




ELSEVIER

Contents lists available at ScienceDirect

Critical Reviews in Oncology / Hematology

journal homepage: www.elsevier.com/locate/critrevonc

GEORCC recommendations on target volumes in radiotherapy for Head Neck Cancer of Unknown Primary

Joaquín Cabrera Rodríguez^{a,*}, Jon Cacicedo^b, Jordi Giralt^c, Enrique García Miragall^d, Marta Lloret^e, Fernando Arias^f, María Angeles González Ruiz^a, Jorge Contreras^g

^a Radiation Oncology Department, Hospital Universitario Infanta Cristina, Avenida de Elvas, s/n, 06080 Badajoz, Spain

^b Radiation Oncology Department, Hospital Universitario de Cruces, Plaza de Cruces, s/n, 48903 Baracaldo, Spain

^c Radiation Oncology Department, Hospital General Vall D'Hebron, Passeig de la Vall d'Hebron, 119-129, 08035 Barcelona, Spain

^d Radiation Oncology Department, Hospital General Universitario Valencia- ERESA, Avenida Blasco Ibáñez, 17, 46010 Valencia, Spain

^e Radiation Oncology Department, Hospital Universitario Doctor Negrín, c/ Barranco de la ballena, s/n, 35010, Las Palmas de Gran Canaria, Spain

^f Radiation Oncology Department, Complejo Hospitalario de Navarra, C/ Irunlarrea, 4, 31008 Pamplona, Spain

^g Radiation Oncology Department, Complejo Hospitalario Carlos Haya, Avenida de Carlos Haya, s/n, 29010 Málaga, Spain

ARTICLE INFO

Keywords:

Head and neck cancer
Intensity-modulated radiotherapy
Unknown primary
Clinical target volume
Guideline

ABSTRACT

Head Neck Cancer of Unknown Primary (HNCUP) is a rare condition, representing approximately 5–10% of all head neck cancers. Radiotherapy, adjuvant or radical, is usually employed in the treatment of those patients. To date, no specific guidelines for the optimal definition of the target volume to be irradiated have been published. In recent years, there have been advances in the knowledge of the molecular biology of HNCUP, its diagnostic imaging and the implementation of sophisticated radiotherapy techniques with enhanced precision in target localization and treatment delivery. These progresses have provided valuable information about the natural history of HNCUP that will allow for establishment of the best treatment for each patient, including standardized, consistent and reproducible target volumes definitions. Several recommendations regarding how to choose volumes when contouring HNCUP in clinical practice are reported, in order to achieve a high rate of loco-regional control while avoiding unnecessary toxicity.

1. Introduction

Cancer of unknown primary site (CUP) includes a group of metastatic tumors in which, after a thorough staging evaluation, the primary origin is not identified (Jesse et al., 1973). A specific category within CUP is that of metastatic cervical lymph node of unknown primary, or Head Neck Cancer of Unknown Primary (HNCUP). This group is less than 10% of head and neck cancer whereas its most frequent histological diagnosis is squamous cell carcinoma (50–70%) (Strojan et al., 2013). After treatment a small percentage of patients will develop a subsequent mucosal primary (SMP) (Nieder et al., 2001) tumor.

The prognosis of a patient with HNCUP is relatively favorable compared to other CUP (Strojan et al., 2013). In the most recent series, the 5-year overall survival and locoregional control is above 60% and 80%, respectively.

Although no clear consensus on a standard treatment regimen exists, depending on the lymph nodes staging, co-morbidities, patient preferences, as well as the department's policy, the patients will

undergo surgery, radiotherapy or a combination of them with or without chemotherapy. In the specific case of radiotherapy, there are no guidelines to set the Clinical Target Volume (CTV) for these patients, in contrast to other sites of the head and neck. Two are the most controversial issues about the optimal CTV in HNCUP 1) whether there is a need to irradiate the healthy pharyngeal and laryngeal mucosa due to the risk of harboring a hidden tumor, which are themselves the main origins for lymph nodes metastases; and 2) When is required the inclusion of the contralateral uninvolved neck within the CTV. As a result of the lack of consensus, the treatment applied to each patient depends on the criteria of the responsible physician or department's policy.

A recent meta-analysis (Liu et al., 2016) and a general review (Müller von der Grün et al., 2017) about treatment outcomes and optimization of radiation therapy in HNCUP does not shed much light on the optimal definition of CTV nor provide any practical recommendations or guidelines. This absence of indications was justified by the authors arguing that the series were small, retrospective and had a large variety of treatments. Actually, the problem with these two articles (Liu

* Corresponding author.

E-mail address: joaquin.cabrera@salud-juntaex.es (J. Cabrera Rodríguez).

et al., 2016; Müller von der Grün et al., 2017) is that they included in the analysis historical series before to the introduction of Positron Emission Tomography (PET) or PET/computed tomography (CT) scans for diagnostic workup, or that employed techniques for treatment currently considered outdated e.g., traditional two dimensional (2D) radiotherapy

However, in our opinion, recent advances in diagnosis and therapy have provided valuable information about the natural history of HNCUP. These data will allow physicians to establish the best treatment for each patient, based on evidence, including standardized, consistent and reproducible CTV definition.

The aim of this review is to develop a guideline to define the CTV for the radiation treatment of HNCUP patients (adjuvant or radical) based on current data involving molecular, clinical and therapeutic aspects.

2. Current evidence about the site of origin of the unknown primary

2.1. Evidence from current radiological and surgical series

In patients with HNCUP, the oropharynx is the most frequent location that hides a squamous cell carcinoma (Nieder et al., 2001; Cianchetti et al., 2009). If, following a physical, endoscopic and radiological exhaustive examination, the origin of HNCUP is not discovered, the usual follow up procedure is to perform a blind biopsy of the nasopharynx and oropharynx (with or without tonsillectomy) and/or other mucosal suspicious sites (Waltonen et al., 2009). PET/CT can identify the origin of the primary in approximately 40% of patients presenting with suspected HNCUP (Wong et al., 2012; Cacicedo et al., 2016) in whom the primary tumor has not been detected after a rigorous evaluation, including standard diagnostic imaging with CT or IMR and endoscopy. The palatine tonsils or the base of tongue are the primary locations in 80–90% of the cases (Cianchetti et al., 2009; Motz et al., 2016).

Laser microsurgery and transoral robotic surgery (TORS) have been postulated effective techniques for diagnostic and therapeutic management of these patients. In a systematic review by Fu et al. (2016), an occult tumor was diagnosed in 111 out of 130 cases (80%). It was located in the oropharynx in 72% of the patients (palatine tonsil in 34, lingual tonsil in 60) but in 18 cases the site was not specified (one patient was diagnosed with two synchronous tumors in the palatine and lingual tonsils).

Overall, after all these referred procedures, an occult tumor can be diagnosed in approximately 50% of the cases.

2.2. Evidence from molecular biology

The histological and immunohistochemical tests may point to the possible primary origin of the nodal metastasis. When the diagnosis is a metastasis of squamous cell or undifferentiated carcinoma, the molecular research can be helpful in determining the tumor lineage. In a review on the incidence of human papillomavirus (HPV) in HNCUP (Boscolo-Rizzo et al., 2015), patients with an initial diagnosis of HNCUP had a positive prevalence for HPV-DNA, p16, or both in 81.8%, 86.2%, and 80.8% respectively. In a recent study (Cheol Park et al., 2017), the sensitivity of p16 was 85.7% and the accuracy of HPV was 85.2% both being higher than fluorine 18 (^{18}F) fluorodeoxyglucose (FDG) PET/CT sensitivity and accuracy (42.9% and 68.5% respectively, $p < 0.05$) to detect a primary tumor hidden in the oropharynx.

Feinmesser et al. (1992) demonstrated that the presence of Epstein-Barr virus (EBV) in the HNCUP was predictive to develop an emerging tumor in the nasopharynx and also that the non-nasopharyngeal squamous cell carcinomas of the head and neck are not related to EBV infection. In the past, the nasopharynx was a frequent site of occult tumors in patients with HNCUP due to the absence of clinical symptoms and difficult access for examination, at present, that situation has

changed because of the use of exhaustive radiological and endoscopic workup in patients with a suspected HNCUP. Therefore, in the absence of molecular evidence of EBV infection, it is reasonable to dismiss the nasopharynx as the origin of HNCUP. Other authors have confirmed these findings (Barker et al., 2009).

The analysis of microRNA (Barker et al., 2009; Masood et al., 2015) (miRNA) is another tool to diagnose with HNCUP. Barker et al. (2009) showed that in patients with cancers of the nasopharynx, tonsil and base of tongue, miRNA expression profile is specific for each site and remained consistent in lymph node metastases. Therefore, in these patients this test can help to predict the origin site of the metastatic disease.

2.3. Evidence from the onset of SMP

After treatment, a proportion of patients with HNCUP will develop SMP. Since head and neck cancer patients are at elevated risk of second primary tumors and because radiotherapy has been considered able to prevent the onset of SMP, some authors advocate a comprehensive irradiation of the healthy pharynx-larynx mucosa. For this reason, it would be interesting to know whether the locations of SMP show a pattern similar to the second primary tumors arising in patients with an index head and neck cancer as this information could either support or to rule out the indication of mucosal irradiation in accordance with the sites at risk involved.

Grau et al. (2000) analyzed the outcomes of 352 patients with HNCUP, treated from 1975 to 1995, included in a national survey of oncologic centers in Denmark. They found that the incidence of a SMP when the mucosa was not irradiated was higher than when it was performed (54% vs. 15%, $p < 0.0001$). Half of the cases of SMP were located in the oropharynx. It is important to note that this series consisted of patients treated before the appearance of current diagnostics imaging techniques and molecular biology test for the staging and characterization of neoplasm. So, in an unknown proportion of cases an occult primary could be unnoticed due to the lack of precise diagnosis compared with the current era. Erkal et al. (2001) compared the onset of SMP in a series of 126 cases of HNCUP, where all the patients received elective mucosal irradiation, according to the incidence of SMP in the center's historical series ($n = 1$ e onset of SMP in a series of 126 cases of HNCUP, where all the patients received elective mucosal irradiation, according to the incidence of SMP in the center's historical series ($n = 1112$) irradiated by a index cancer of the head and neck. They did not find significant differences in the proportion of SMP 13% vs. 9% ($p = 0,81$) Unfortunately details about the distribution of SMP in each mucosal subsite is not provided. The authors' conclusion was that radiotherapy prevented the onset of SMP, but an alternative hypothesis was that due the incidence of SMP after comprehensive mucosal irradiation did not differ from non-comprehensive treatment, radiotherapy to the healthy mucosa did not influence the onset of new primary.

What is the pattern of location of second primary in patients with an index head and neck cancer? Birkeland et al. (2016) carried out a population analysis with the SEER database on the incidence and location of SMP in patients treated for head and neck cancer in a cohort of 58,363 cases. They reported a 3% (1746 cases) of SMP in the head and neck. The oral cavity was the most frequent site of SMP for any previous location of the primary index (58.4%), followed by the larynx (18.2%) and the oropharynx (13.3%).

In conclusion, evidence suggest that occult primary and SMP in HNCUP have distinctive pattern of location and not related to the onset of second primary in patients with an index head and neck cancer. The most common location of SPM patients with UPHNC is the oropharynx, while in patients with an index head neck cancer the usual location of a second primary are oral cavity or larynx, on the contrary a second primary involving the oropharynx is far less common. Furthermore, TORS series aforementioned have demonstrated that occult tumors are

located almost exclusively in the oropharynx. Because of that, it can be assumed that in patients with UPHNC the entire healthy mucosa of the upper aero digestive track is not at risk of harboring an occult tumor.

3. Outcome after three-dimensional conformal radiotherapy and Intensity-Modulated Radiotherapy

There is no published detailed analysis of patterns of recurrence in series of patients with HNCUP staged with current diagnostic methods and treated with radiotherapy based on imaging CTV delimitation, i.e. three-dimensional conformal radiotherapy (3DCRT) and intensity-modulated radiotherapy (IMRT). The impact of the new technology is translated, on one hand, in greater diagnostic accuracy and therefore the selection of patients with true HNCUP and, on the other hand, in a more accurate conformation of isodoses to the anatomical detail accomplished, especially by IMRT that allows the adjustment of the dose of radiotherapy to the CTV and better protection of tissues that do not need to be treated. The results from contemporary series will allow the design of CTV based on reliable data. As a result, the precision in depiction of the outcomes after conformal radiotherapy related to “in field/out field” failure as well as location of SMP, is greater and no longer comparable to outdated radiotherapy techniques such as 2D.

In order to identify articles to evaluate the use of 3DCRT and/or IMRT in HNCUP patients undergoing radiotherapy with or without previous surgery, we performed a comprehensive literature research in MEDLINE database without any limits to identify relevant studies (published up to 15 June 2017) dealing with the topic of this review. We used the following keywords “head and neck cancer” AND “unknown primary” AND “radiotherapy” AND “conformal-radiotherapy” AND “intensity-modulated”. The titles and abstracts were examined for potentially eligible studies for full-text retrieval. Results are presented in Table 1. In addition, the most significant articles are detailed in the text. Additional sources were identified from references cited in the articles identified by electronic searching.

3.1. Results

Twenty-two studies were identified (Klem et al., 2008; Ligey et al., 2009; Lu et al., 2009; Madani et al., 2008; Frank et al., 2010; Fakhrian et al., 2012; Chen et al., 2011; Shoushtari et al., 2011; Sher et al., 2011; Perkins et al., 2012; Mourad et al., 2014; Janssen et al., 2014; Villeneuve et al., 2012; Hosni et al., 2016; Richards et al., 2016; Demiroz et al., 2014; Straetmans et al., 2015; Cuaron et al., 2016; de Ridder et al., 2017; Al Kadah et al., 2017; Du et al., 2017; Hu et al., 2017) matching series of patients treated with 3DCRT or IMRT, covering a treatment time period from 1989 to 2016. For the analysis, three publications were excluded: Former articles by Klem et al. (2008) and Mourad et al. (2014) were updated, so the most recent versions (Cuaron et al., 2016; Hu et al., 2017) were used for this study. The Du et al. series (Du et al., 2017) was also excluded because it was not considered representative of the index-case with HNCUP, since it was a work focused exclusively on retropharyngeal metastasis without diagnosis of nasopharyngeal primary, in the Chinese population. The review was carried out with a total of 19 articles totaling 942 cases. All the series were retrospective studies except the study by Richards et al. (2016) which was a prospective one. Table 1 depicts main outcomes in staging and treatment of all remaining 19 publications.

The use of PET or PET/CT is detailed in 14 publications (403 patients, 42.8%) In 4 series, the number of patients staged with PET or PET/CT was not specified and in one article PET was not used in any case. CT and Magnetic Resonance Imaging (MRI), plus oral pan endoscopy with selective biopsy of suspicious mucosa were used in all cases. Diagnostic tonsillectomy was used in 14 of the series, but only in 4 of them all the patients included received it. In the remaining cases its use was variable; in 5 series no patient received a tonsillectomy.

Regarding the treatment administered: 617 patients received

radiotherapy as adjuvant therapy and 325 as radical therapy (usually associated with chemotherapy and according to response with elective rescue surgery too) Radiotherapy exclusively to the involved neck was used in 191 (20.3%) patients, with or without mucosal irradiation, while 751 (79.7%) patients received bilateral cervical irradiation plus mucosal radiotherapy, usually to the full pharynx - larynx mucosa. Overall, the guidance to define elective volumes of irradiation was not detailed except in Janssen (Janssen et al., 2014) and de Ridder's (de Ridder et al., 2017) publications which outlined CTV protocol according to the neck stage and involved lymph node level. Most of the authors chosen the irradiation of the ipsilateral neck, levels I to V, plus retropharyngeal and retro-styloid along with the contralateral neck as standard CTV; levels II to IV were included when the contra lateral neck was cN0, and levels I-V if the contra lateral neck was also infiltrated with metastasis.

When elective irradiation of the mucosa was employed, standard CTV comprised the entire pharyngeal axis (from nasopharynx to hypopharynx) plus larynx in all series, except in 3 groups where CTV is limited to oropharynx. Only Straetmans et al. (2015) did not indicate mucosal irradiation routinely.

It is important to note that the potential influence of random and systematic errors in patient's daily positioning was not taken in to account in any of the studies where the site of relapse or SMP was analyzed. So, the definition of mucosal relapse or development of a SMP, for the purposes of this review, was done on the basis of the investigator's intention to encompass the healthy mucosa as an elective CTV.

3.2. Neck recurrences

Overall, 117 cervical recurrences were reported (12.4% of total number of patients) 97 of which (83.2% of the total number of recurrences) occurred in the ipsilateral neck, especially in patients with lymph node stage N2B - N3. There were only 20 cases of contra lateral neck relapse (2% of the patients). There were 11 contralateral relapses in the group of patients treated with unilateral irradiation versus 9 in the bilateral irradiation group. Al Kadah (Al Kadah et al., 2017) did not provide a detailed description of the site of cervical recurrences in his series. The relationship between intention of radiotherapy (adjuvant or radical) and neck failure was described in 13 series: a total of 27 recurrences occurred in patients with adjuvant treatment and 16 in patients with radical radiotherapy. In six articles there are no a full description of the pattern of recurrences the by treatment group.

3.3. Subsequent mucosal primary

Only 34 cases (3.5%) of SMP were diagnosed; 9 in the unilateral irradiation group and 22 in the bilateral treatment group. In two series, the authors did not specify in which treatment group the SMP emerged. The most frequent locations for SMP were in the oropharynx in 14 cases (40%), hypopharynx in 7 (20%) and larynx in 5 (17.8%) There was only one case of SMP in the nasopharynx.

We analyzed the rate of neck relapse as well as SMP incidence by treatment group using the χ^2 test. The results are depicted in Table 2.

Although contralateral recurrences are significantly more frequent in patients who receive unilateral radiotherapy, the clinical relevance of this data is very limited considering that this event is exceptional (2%). The low frequency of regional recurrence is striking, considering that most patients were treated in stages IVa - IVb, thus confirming the relative good prognosis of this clinical entity. We did not find any significant difference regarding the incidence of SMP between patients treated with unilateral or bilateral radiotherapy.

Although the published series have relatively few patients, the total number of them is almost one thousand, so the information provided by these works is relevant.

Table 1
3DCRT or IMRT for HNCUP. Review of published series.

Author (Ref)	N	Period	Radiotherapy Plan ^b	Adjuvant RT	Radical RT	Elective CTV	PET or PET/CT (n)	Tonsillectomy	Neck Failure. Contralateral	Neck Failure. Total	Loco-regional recurrence. Adjuvant	Loco-regional recurrence. Radical	SMP (site)	Overall regional Control.	Overall Survival
Madani (Madani et al., 2008)	23	2003-6	B + M.	19	4	CTV _M = NP-OP-HPH. CTV _N = Ib-V, rPHg	3	Yes	0	1	0	1	0	NS	74,8% (2 y)
Lu (Lu et al., 2009)	18	2000-6	U + IM: 1 B + IM: 17	12	6	CTV _M = NP-OP. CTV _N = NS	15	100%	0	2	0	2	1	88,5% (2 y)	74,2% (2 y)
Frank (Frank et al., 2010)	52	1998-2005	B + IM.	12	40	CTV _M = NP-OP-L. CTV _N = Ib-V, rPHg	26	32%	1	3	0	2	1	94,2% (5 y)	81% (5 y)
Sher (Sher et al., 2011)	24	200-9	B + IM	3	21	CTV _M = N-OP-L-HPH. CTV _N = Ib-V, rPHg	24	46%	0	0	0	0	0	100% (2 y)	92% (2 y)
Chen (Chen et al., 2011)	51	2001-9	B + IM.	39	12	CTV _M = Ib-V. CTV _N = N-OP-L-HPH.	19	100%	1	4	NS	0	2	86% (2 y)	84% (2 y)
Shoushtari (Shoushtari et al., 2011)	27	2002-8	B + IM.	4	23	CTV _M = NS. CTV _N = NS, but always rPHg	27	No	0	3	NS	0	0	88,5% (5 y)	70,9% (5 y)
Villeneuve (Villeneuve et al., 2012)	25	2005-8	B + M	0	25	CTV _M = N-OP-L-HPH. CTV _N = NS	25	Yes	0	0	0	0	0	100% (3 y)	100% (3 y)
Demiroz (Demiroz et al., 2014)	41	1994-2009	B + IM	22	19	CTV _M = N-OP-L-HPH. CTV _N = I-V	NS	27%	0	2	1	1	2	90,9% adjuvant 88,6% radical (4 y)	85,3% adjuvant 85,6% radical (4 y)
Hu (Hu et al., 2017)	60	1998-2011	B + M	49	11	CTV _M = OP. CTV _N = NS	43	100%	0	5	1	4	4	90% (5 y)	76% (5 y)
Richards (Richards et al., 2016)	36	2007-12	B + IM	36	0	CTV _M = N-OP-L-HPH. CTV _N = I-V	36	Yes	1	3	3	0	1	89,8% (2 y)	81,3% (2 y)
Janssen (Janssen et al., 2014)	28	2006-12	U: 15 + IM:2 B: + IM: 13	20	8	rPHg. CTV _M = OP. CTV _N = risk based.	28	No	0	0	0	2	0	93% (3 y)	76% (3 y)
Perkins (Perkins et al., 2012)	46	1989-2008	U: 21 B + IM: 25	40	6	CTV _M = No. CTV _N = NS. CTV _M = N-OP at least.	23	No	1	1	1	0	2	NS	87% (2 y) 77% (5 y)
Fakhrian (Fakhrian et al., 2012)	65	1988-2009	U: 17 B + IM: 48	61	4	CTV _M = No. CTV _N = NS. CTV _M = N-OP-L-HPH. CTV _N = NS	46	66%	1	1	8	0	0	NS	71% (2 y) 48% (5 y)

(continued on next page)

Table 1 (continued)

Author (Ref)	N	Period	Radiotherapy Plan ^b	Adjuvant RT	Radical RT	Elective CTV	PET or PET/CT (n)	Tonsillectomy	Neck Failure. Contralateral	Neck Failure. Total	Loco-regional recurrence. Adjuvant	Loco-regional recurrence. Radical	SMP (site)	Overall loco-regional Control.	Overall Survival	
Ligey (Ligey et al., 2009)	95	1990-2007	U: 59, IM:5	79	16	CTV _M = PH CTV _N = NS	13	5%	6	20	NS	NS	7 INP, 2OP, 2HPH, 2L	NS	22% (5 y)	
Straetmans (Straetmans et al., 2015)	48	1997-2010	U: 32 IM:6 B: 16	48	0	CTV _M = PH CTV _N = NS	NS	100%	3	6	9	0	2 2OC	NS	23% (5 y)	
Hosni (Hosni et al., 2016)	61	2005-13	U: 15 B:46 MI:15	19	42	CTV _M = No. CTV _N = NS	0	100%	0	0	NS	0	1 IOP	NS	54,9% (5 y)	
Al Kadah (Al Kadah et al., 2017)	81 ^a	1991-2013	U: 14 B: 67 + MI	62	19	CTV _M = NS CTV _N = II-V CTV _M = PH CTV _N = II-V	NS	No	NS	20	NS	NS	2 IOP, IOC	NS	45% (2 y) 30% (5 y)	
de Ridder (de Ridder et al., 2017)	76	2006-2016	U: 11 + MI B: 65 + MI	39	41	CTV _M = PH CTV _N = I-V	78	19%	0	8	0	8	0	0	90% (3 y)	67% (3 y) 62% (5 y)
Cuaron (Cuaron et al., 2016)	85	1995-2012	U: 6 B + MI: 79	53	32	CTV _M = NS CTV _N = N -OP-L-HPH CTV _N = I-V	NS	No	0	11	NS	NS	1 IOC	86,4% (5 y)	74,5% (5 y)	

Notes: U = Unilateral Radiotherapy. B = Bilateral Radiotherapy. MI = Mucosal Irradiation. CTV_M = CTV mucosal. OC = Oral Cavity, NP = Nasopharynx, OP = Oropharynx, PH = Pharynx, L = Larynx, HPH = Hypopharynx, CE = Cervical Esophagus, rPHg = Retropharyngeal. CTV_N = CTV nodal. NS = No stated. Y = year.

^a 8 patients had metastatic disease at diagnosis.

^b Radiotherapy plan denotes whether the neck volume treated was unilateral or bilateral as well as if mucosal irradiation was employed; numerals indicated number of patients included in each group.

Table 2
Analysis of neck failure and subsequent mucosal primary according to the neck volume of irradiation.

Elective Neck Target Volume	Contralateral neck failure ^a	Overall neck failure ^a	Subsequent Mucosal Primary ^b
Ipsilateral Neck	11/177 (6,2%)	28/177 (15,2%)	9/145 (6,2%)
Bilateral Neck	9/684 (1,3%)	69/684 (10,1%)	22/668 (3,3%)
Significance (χ^2)	P = 0,0001	P = 0,03	P = 0,09

Notes:

^a Al Kadah et al. (2017) series was excluded in the analysis because they do not match neck recurrences according to the target volume irradiated.

^b Al Kadah et al. (2017) and Straetmans et al. (2015) series were excluded in the analysis because they did not specify the onset of SMP by treatment group.

4. Recommendations for CTV selection in HCUP

The GEORCC’s recommendations for mucosal and neck CTV selection are summarized in Table 3 including patients treated with adjuvant or radical radiotherapy. For the definition of the different node levels, the consensus of 2013 (Grégoire et al., 2014) has been used.

4.1. Mucosal CTV

Currently there is no data to advise the routine irradiation to the full pharyngeal and laryngeal mucosa, since occult cancers or SMP appear, chiefly, in the oropharynx either after the staging or treatment. Furthermore, the omission of radiotherapy to the mucosa does not appear to increase the incidence of SMP either (Table 2). It should be noted that the incidence of SMP in the current series of HNCUP is very low compared to old ones while it also shows a pattern of presentation which differs from second primary trend found after a former head and neck cancer (Birkeland et al., 2016). However, it should be stressed that the dose received by the pharyngeal and laryngeal mucosa, even when elective irradiation is not intended, could be as high as when these sites are purposefully included in the CTV, as Perkins et al. (2012) demonstrated, due to its anatomical proximity with high risk nodal areas (especially in the parapharyngeal space). We suggest that the ipsilateral

Table 3
GEORCC recommendations on CTV selection in radiotherapy for HNCUP.

Stage (AJCC 7th edition, 2010)	Radiotherapy Approach.	Elective CTV.	Remarks
T0 pN1 (no ENE)	No.	Not applicable.	Mucosal irradiation: 1) Ipsilateral oropharynx if HVP +/P16 + is found on node biopsy or HPV/P16 status is unknown. 2) Nasopharynx. If EBV is found on node biopsy or when only level V is involved.
T0 pN1 (ENE +) T0 cN1	Ipsilateral neck ^a ± pharyngeal mucosa.	Mucosal Irradiation. Neck levels: II-IV, VIIa-b.	
T0 pN2A, B. T0 cN2A, B.	N2A. Ipsilateral neck ^a only ± pharyngeal mucosa. N2B. Ipsilateral neck ^a . Consider bilateral irradiation when > 2 infiltrated nodes.	Ipsilateral pharyngeal mucosa. Ipsilateral neck levels: II-IV, VIIa-b. ^{b,c} Contralateral neck levels: II-IV. ^d	
T0 N2C T0 pN3 T0 cN3	Bilateral neck ^a ± pharyngeal mucosa.	Ipsilateral pharyngeal mucosa. Ipsilateral neck levels: II-V, VIIa-b. ^{b,c} Contralateral neck levels: II-IV. ^d	Avoiding mucosal irradiation: 1) Whenever HPV/p16 or EBV is negative. 2) Former/Blank tonsillectomy. 3) Only level I, III, IV or V (EBV-negative) is involved. Neck treatment. 1) Unilateral irradiation of the involved neck is encouraged for stages N1 N2A, N2B up to 2 positive nodes. 2) Routine encompasses of levels I to V for all patients is not recommended. Elective levels to irradiate should be select according to risk. 3) Cover bilateral levels VIIa-b if EBV-positive.

Notes:

ENE = Extra Nodal Extension.

^a Plus boost to the involved level in the postoperative setting or to the macroscopic nodes plus a margin in case of radical radiotherapy.

^b Stage N2B or higher and involved levels II, III or IV: level V should be encompassed.

^c Ipsilateral level IB should be included when neck stage is N2B – 3.

^d Elective CTV when contralateral neck is N0.

oropharynx should be included in all cases, except if the tonsillectomy was negative, or if a HPV infection is not demonstrated. Janssen et al. (2014) also skips oropharyngeal irradiation when the involved lymph node is located exclusively at I, III or IV level. Nowadays occult undifferentiated nasopharyngeal cancer is not as relevant entity as in the past (only one case described in the current review) Nasopharynx should be included in the CTV when the lymph node biopsy is positive for EVB or if the compromised nodal level is the V. Fig. 1 depicts examples for CTV mucosal delineation in nasopharynx, tonsil and base of tongue.

Although the authors acknowledge that there is not strong evidence, thus far, to support routinely the irradiation of nasopharynx or oropharynx in patients with EBV-positive or HPV-positive UPHNC, our literature review, support that in these cases the origin of the neoplasm is usually located in these areas. It therefore makes sense its elective irradiation when the molecular biology suggests that source.

4.2. Nodal CTV

Routine encompassing of levels I to V in all patients is not recommended (Hamoir et al., 2014), since no mucosal site of the head and neck presents a significant risk of simultaneous involvement for all cervical lymph node areas.

The majority of patients with a suspected HNCUP have an occult carcinoma in the oropharynx or will develop a PMS on this site. In addition, up to 90% of these patients express molecular factors associated with HPV infection (Motz et al., 2016; Keller et al., 2014). Therefore, it seems reasonable to propose elective volumes for lymph node irradiation based on the neck levels at risk for oropharyngeal carcinoma in patients with HPV-positive HNCUP. In fact, three groups (Shoushtari et al., 2011; Janssen et al., 2014; Hu et al., 2017) have employed an approximation of HNCUP treatment based on oropharynx protocols and their results are superimposable to those obtained with the standard approach with full mucosa irradiation. Those data corroborates the safety of unilateral elective irradiation at stage pN1, pN2a and pN2b with up to 2 affected nodes; in the most advanced cases the general practice is bilateral cervical irradiation, including at least levels II–IV for cN0. A controversial aspect is whether to consider level IB as high-risk level for all cases because of its low incidence. In our view, the

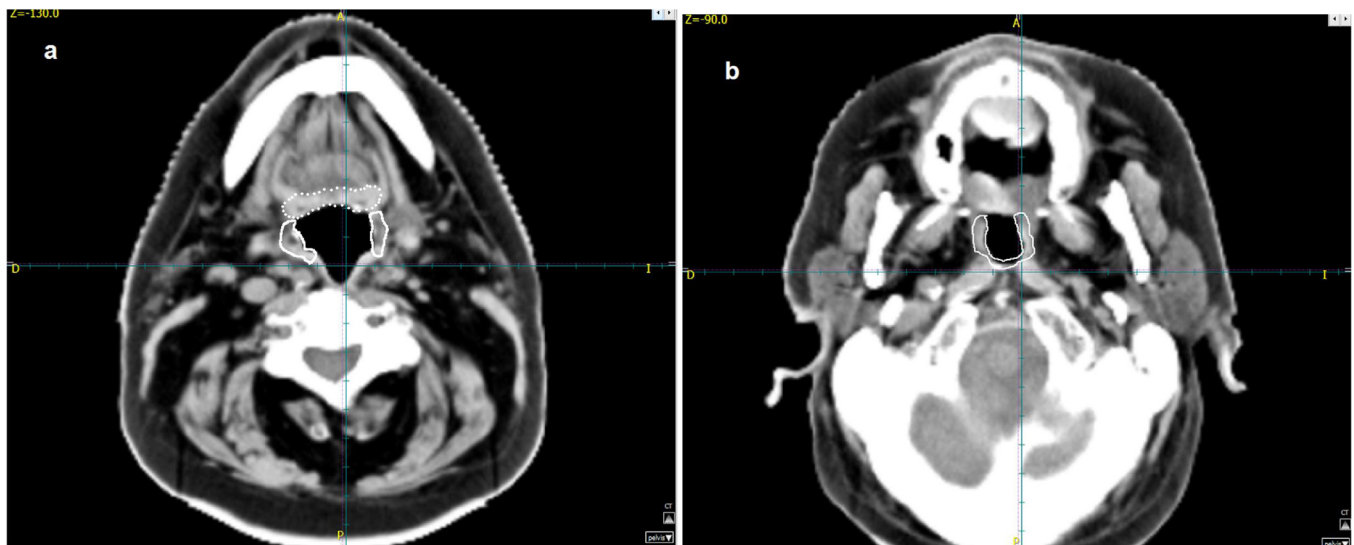


Fig. 1. Mucosal CTV.

Notes: Fig. 1a. CTV delineation for tonsils (continuous line) and base of tongue (dotted line). Ipsilateral oropharynx should be part of the CTV when indicated (see Table 3). Only mucosa of the oropharynx and associated lymphoid tissue are included in the target volume (muscles and pharyngeal wall are excluded). Fig. 1b. Example of mucosal CTV for nasopharynx delineation in case of VEB +.

available evidence suggests that it should not be included routinely as part of the volume of treatment: Firstly, the submandibular region is neither the first area of tonsil drainage nor the base of the tongue (Grégoire et al., 2014) secondly, recent surgical series (Sanguineti et al., 2014; Lee et al., 2017; Yu et al., 2015) have shown that the risk of pathological involvement of level IB is less than 10% in patients with lymph node stage pN0-2a or pN2b (up to 2 positive lymph nodes) Contralateral involvement is also infrequent. To date, there are no definitive definite data about safety of unilateral neck irradiation in patients with stage N2b-c to 3. Current evidence suggests that it is probably safe when the neck stage is not advanced. Studies are underway to resolve this issue (www.clinicaltrials.gov identification: NCT02572661) Using the example of ASTRO for irradiation in patients with non-advanced oropharyngeal cancer (Sher et al., 2017) can be recommend exclusive ipsilateral neck treatment in selected cases.

Regarding the irradiation of the contralateral N0 neck, there is no consensus on the neck levels to be included in case of elective contralateral neck irradiation. Levels II to IV are the areas at the highest risk of involvement and therefore should be included as elective volume. IVb level can probably be omitted in these cases (Grégoire et al., 2016).

In patients with EVB-positive HNCUP, nodal CTV should comprise bilateral retropharyngeal lymph nodes and ipsilateral V level. Routine coverage of the ipsilateral IB level is not advised except in cases of bulky nodal involvement, or when there is bilateral involvement or in case of extranodal extension (Zhang et al., 2015). When contralateral neck is negative, it is considered safe not to include levels IV and Vb as part of the nodal CTV (Ho et al., 2012; Lee et al., 2013).

5. Conclusions

The CTV should be adapted to the level of risk for each case as the routine irradiation of the mucosa and bilateral neck has not been shown to improve the survival, while it is more toxic. After conducting a comprehensive study to diagnose an occult primary in HNCUP patient, ipsilateral oropharyngeal irradiation is recommended according to the hints described in Table 3. Comprehensive radiotherapy to the mucosa of the pharynx and larynx is discouraged.

Regarding CTV of the neck, it is suggested: 1) to avoid routine treatment of levels I to V in all cases; and 2) to adapt the elective nodal CTV of irradiation according to the N stage and level involved. Patients

at low risk of contralateral metastases (N1 - N2A, N2B with ≤ 2 affected lymph nodes) can be safely treated by ipsilateral neck radiotherapy. Those with stage N2B > 2 positive nodes, or N2C - N3 should receive bilateral neck irradiation.

Conflicts of interest

All the authors have no conflicts of interest.

Financial support

This research did not receive any specific grant from funding agencies in the public, commercial, or not-for-profit sectors

References

- Al Kadah, B., Pappaspyrou, G., Linxweiler, M., Schick, B., Rube, C., Büchler, B.S., Niewald, M., 2017. Cancer of unknown primary (CUP) of the head and neck: retrospective analysis of 81 patients. *Eur. Arch. Otorhinolaryngol.* 274 (June (6)), 2557–2566. <https://doi.org/10.1007/s00405-017-4525-8>.
- Barker, E.V., Cervigne, N.K., Reis, P.P., Goswami, R.S., Xu, W., Weinreb, I., Irish, J.C., Kamel-Reid, S., 2009. microRNA evaluation of unknown primary lesions in the head and neck. *Mol. Cancer* 8 (December), 127. <https://doi.org/10.1186/1476-4598-8-127>.
- Birkeland, A.C., Rosko, A.J., Chinn, S.B., Prince, M.E., Sun, G.H., Spector, M.E., 2016. Prevalence and outcomes of head and neck versus non-head and neck second primary malignancies in head and neck squamous cell carcinoma: an analysis of the surveillance, epidemiology, and end results database. *ORL J. Otorhinolaryngol. Relat. Spec.* 78 (2), 61–69.
- Boscolo-Rizzo, P., Schroeder, L., Romeo, S., Pawlita, M., 2015. The prevalence of human papillomavirus in squamous cell carcinoma of unknown primary site metastatic to neck lymph nodes: a systematic review. *Clin. Exp. Metastasis* 32 (December (8)), 835–845. <https://doi.org/10.1007/s10585-015-9744-z>.
- Cacicedo, J., Navarro, A., Del Hoyo, O., Gomez-Iturriaga, A., Alongi, F., Medina, J.A., Elicin, O., Skanjeti, A., Giammarile, F., Bilbao, P., Casquero, F., de Bari, B., Dal Pra, A., 2016. Role of fluorine-18 fluorodeoxyglucose PET/CT in head and neck oncology: the point of view of the radiation oncologist. *Br. J. Radiol.* 89 (November (1067)), 20160217.
- Chen, A.M., Li, B.Q., Farwell, D.G., Marsano, J., Vijayakumar, S., Purdy, J.A., 2011. Improved dosimetric and clinical outcomes with intensity-modulated radiotherapy for head-and-neck cancer of unknown primary origin. *Int. J. Radiat. Oncol. Biol. Phys.* 79 (March (3)), 756–762.
- Cheol Park, G., Roh, J.L., Cho, K.J., Seung Kim, J., Hyeon Jin, M., Choi, S.H., Yuhl Nam, S., Yoon Kim, S., 2017. (18) F-FDG PET/CT vs. human papillomavirus, p16 and Epstein-Barr virus detection in cervical metastatic lymph nodes for identifying primary tumors. *Int. J. Cancer* 140 (March (6)), 1405–1412. <https://doi.org/10.1002/ijc.30550>.
- Cianchetti, M., Mancuso, A.A., Amdur, R.J., Werning, J.W., Kirwan, J., Morris, C.G.,

- Mendenhall, W.M., 2009. Diagnostic evaluation of squamous cell carcinoma metastatic to cervical lymph nodes from an unknown head and neck primary site. *Laryngoscope* 119 (December (12)), 2348–2354. <https://doi.org/10.1002/lary.20638>.
- Cuaron, J., Rao, S., Wolden, S., Zelefsky, M., Schupak, K., Mychalczak, B., Lee, N., 2016. Patterns of failure in patients with head and neck carcinoma of unknown primary treated with radiation therapy. *Head Neck* 38 (April (Suppl 1)), E426–31. <https://doi.org/10.1002/hed.24013>.
- de Ridder, M., Klop, M., Hamming-Vrieze, O., de Boer, J., Jasperse, B., Smit, L., Vogel, W., van den Brekel, M., Al-Mamgani, A., 2017. Unknown primary head and neck squamous cell carcinoma in the era of fluorodeoxyglucose-positron emission tomography/CT and intensity-modulated radiotherapy. *Head Neck* 39 (July (7)), 1382–1391. <https://doi.org/10.1002/hed.24762>.
- Demiroz, C., Vainshtein, J.M., Koukourakis, G.V., Gutfeld, O., Prince, M.E., Bradford, C.R., Wolf, G.T., McLean, S., Worden, F.P., Chepeha, D.B., Schipper, M.J., McHugh, J.B., Eisbruch, A., 2014. Head and neck squamous cell carcinoma of unknown primary: neck dissection and radiotherapy or definitive radiotherapy. *Head Neck* 36 (November (11)), 1589–1595.
- Du, C., Ying, H., Zhang, Y., Huang, Y., Zhai, R., Hu, C., 2017. Treatment for retropharyngeal metastatic undifferentiated squamous cell carcinoma from an unknown primary site: results of a prospective study with irradiation to nasopharyngeal mucosa plus bilateral neck. *Oncotarget* 8 (June (26)), 42372–42381. <https://doi.org/10.18632/oncotarget.16344>.
- Erkal, H.S., Mendenhall, W.M., Amdur, R.J., Villaret, D.B., Stringer, S.P., 2001. Squamous cell carcinomas metastatic to cervical lymph nodes from an unknown head-and-neck mucosal site treated with radiation therapy alone or in combination with neck dissection. *Int. J. Radiat. Oncol. Biol. Phys.* 50 (May (1)), 55–63.
- Fakhrian, K., Thamm, R., Knapp, S., Molls, M., Pigorsch, S., Haller, B., Geinitz, H., 2012. Radio(chemo)therapy in the management of squamous cell carcinoma of cervical lymph nodes from an unknown primary site. A retrospective analysis. *Strahlenther. Onkol.* 188 (January (1)), 56–61.
- Feinmesser, R., Miyazaki, I., Cheung, R., Freeman, J.L., Noyek, A.M., Dosh, H.M., 1992. Diagnosis of nasopharyngeal carcinoma by DNA amplification of tissue obtained by fine-needle aspiration. *N. Engl. J. Med.* 326 (January (1)), 17–21.
- Frank, S.J., Rosenthal, D.I., Petsuksiri, J., Ang, K.K., Morrison, W.H., Weber, R.S., Glisson, B.S., Chao, K.S., Schwartz, D.L., Chronowski, G.M., El-Naggar, A.K., Garden, A.S., 2010. Intensity-modulated radiotherapy for cervical node squamous cell carcinoma metastases from unknown head-and-neck primary site: M. D. Anderson Cancer Center outcomes and patterns of failure. *Int. J. Radiat. Oncol. Biol. Phys.* 78 (November (4)), 1005–1010.
- Fu, T.S., Foreman, A., Goldstein, D.P., de Almeida, J.R., 2016. The role of transoral robotic surgery, transoral laser microsurgery, and lingual tonsillectomy in the identification of head and neck squamous cell carcinoma of unknown primary origin: a systematic review. *J. Otolaryngol. Head Neck Surg.* 45 (May (1)), 28. <https://doi.org/10.1186/s40463-016-0142-6>.
- Grau, C., Johansen, L.V., Jakobsen, J., Geertsen, P., Andersen, E., Jensen, B.B., 2000. Cervical lymph node metastases from unknown primary tumours. Results from a national survey by the Danish Society for Head and Neck Oncology. *Radiother. Oncol.* 55 (May (2)), 121–129.
- Grégoire, V., Ang, K., Budach, W., Grau, C., Hamoir, M., Langendijk, J.A., Lee, A., Le QT, Maingon P., Nutting, C., O'Sullivan, B., Porceddu, S.V., Lengele, B., 2014. Delineation of the neck node levels for head and neck tumors: a 2013 update. *DAHANCA, EORTC, HKNPCSG, NCIC CTG, NCRI, RTOG, TROG consensus guidelines*. *Radiother. Oncol.* 110 (January (1)), 172–181. <https://doi.org/10.1016/j.radonc.2013.10.010>.
- Grégoire, V., Duprez, T.P., Lengelé, B., Hamoir, M., 2016. *Clinical Radiation Oncology*, 4th ed. Elsevier, Philadelphia, pp. 738–762 Chapter 41, Management of the neck.
- Hamoir, M., Troussier, I., Machiels, J.P., Reyckers, H., Schmitz, S., Thariat, J., Grégoire, V., 2014. Lymph node metastases from squamous cell carcinoma of unknown primary site. Is it time to change of paradigm? *Bull. Cancer* 101 (May (5)), 455–460. <https://doi.org/10.1684/bdc.2014.1965>.
- Ho, F.C., Tham, I.W., Earnest, A., Lee, K.M., Lu, J.J., 2012. Patterns of regional lymph node metastasis of nasopharyngeal carcinoma: a meta-analysis of clinical evidence. *BMC Cancer* 12 (March), 98. <https://doi.org/10.1186/1471-2407-12-98>.
- Hosni, A., Dixon, P.R., Rishi, A., Au, M., Xu, W., Song, Y., Chepeha, D.B., Goldstein, D.P., Huang, S.H., Kim, J., O'Sullivan, B., Waldron, J., Bratman, S.V., de Almeida, J.R., 2016. Radiotherapy characteristics and outcomes for head and neck carcinoma of unknown primary vs T1 base-of-tongue carcinoma. *JAMA Otolaryngol. Head Neck Surg.* 142 (December (12)), 1208–1215.
- Hu, K.S., Mourad, W.F., Gamez, M.E., Lin, W., Jacobson, A.S., Persky, M.S., Urken, M.L., Culliney, B.E., Li, Z., Tran, T.N., Schantz, S.P., Chadha, J., Harrison, L.B., 2017. Five-year outcomes of an oropharynx-directed treatment approach for unknown primary of the head and neck. *Oral Oncol.* 70 (July), 14–22. <https://doi.org/10.1016/j.oraloncology.2017.05.001>.
- Janssen, S., Glanzmann, C., Huber, G., Studer, G., 2014. Individualized IMRT treatment approach for cervical lymph node metastases of unknown primary. *Strahlenther. Onkol.* 190 (April (4)), 386–393.
- Jesse, R.H., Perez, C.A., Fletcher, G.H., 1973. Cervical lymph node metastasis: unknown primary cancer. *Cancer* 31, 854–859.
- Keller, L.M., Galloway, T.J., Holdbrook, T., Ruth, K., Yang, D., Dubyk, C., Flieder, D., Lango, M.N., Mehra, R., Burtness, B., Ridge, J.A., 2014. p16 status, pathologic and clinical characteristics, biomolecular signature, and long-term outcomes in head and neck squamous cell carcinomas of unknown primary. *Head Neck* 36 (December (12)), 1677–1684. <https://doi.org/10.1002/hed.23514>.
- Klem, M.L., Mechalakos, J.G., Wolden, S.L., Zelefsky, M.J., Singh, B., Kraus, D., Shaha, A., Shah, J., Pfister, D.G., Lee, N.Y., 2008. Intensity-modulated radiotherapy for head and neck cancer of unknown primary: toxicity and preliminary efficacy. *Int. J. Radiat. Oncol. Biol. Phys.* 70 (March (4)), 1100–1107.
- Lee, A.W., Sze, H., Ng, W.T., 2013. Is selective neck irradiation safe for node-negative nasopharyngeal carcinoma? *Int. J. Radiat. Oncol. Biol. Phys.* 85 (March (4)), 902–903. <https://doi.org/10.1016/j.ijrobp.2012.09.010>.
- Lee, N.C., Kelly, J.R., Park, H.S., Yarbrough, W.G., Burtness, B.A., Husain, Z.A., 2017. The risk of level IB nodal involvement in oropharynx cancer: guidance for submandibular gland sparing irradiation. *Pract. Radiat. Oncol.* (February). <https://doi.org/10.1016/j.prro.2017.02.004>. pii: S1879-8500(17)30047-4.
- Lige, A., Gentil, J., Créhange, G., Montbarbon, X., Pommier, P., Peignaux, K., Truc, G., Maingon, P., 2009. Impact of target volumes and radiation technique on loco-regional control and survival for patients with unilateral cervical lymph node metastases from an unknown primary. *Radiother. Oncol.* 93 (December (3)), 483–487. <https://doi.org/10.1016/j.radonc.2009.08.027>.
- Liu, X., Li, D., Li, N., Zhu, X., 2016. Optimization of radiotherapy for neck carcinoma metastasis from unknown primary sites: a meta-analysis. *Oncotarget* 7 (November (48)), 78736–78746. <https://doi.org/10.18632/oncotarget.12852>.
- Lu, H., Yao, M., Tan, H., 2009. Unknown primary head and neck cancer treated with intensity-modulated radiation therapy: to what extent the volume should be irradiated. *Oral Oncol.* 45 (June (6)), 474–479.
- Madani, I., Vakaet, L., Bonte, K., Boterberg, T., De Neve, W., 2008. Intensity-modulated radiotherapy for cervical lymph node metastases from unknown primary cancer. *Int. J. Radiat. Oncol. Biol. Phys.* 71 (July (4)), 1158–1166.
- Masood, Y., Kqueen, C.Y., Rajadurai, P., 2015. Role of miRNA in head and neck squamous cell carcinoma. *Expert Rev. Anticancer Ther.* 15 (February (2)), 183–197. <https://doi.org/10.1586/14737140.2015.978294>.
- Motz, K., Qualliotine, J.R., Rettig, E., Richmond, J.D., Eisele, D.W., Fakhry, C., 2016. Changes in unknown primary squamous cell carcinoma of the head and neck at initial presentation in the era of human papillomavirus. *JAMA Otolaryngol. Head Neck Surg.* 142 (March (3)), 223–228. <https://doi.org/10.1001/jamaoto.2015.3228>.
- Mourad, W.F., Hu, K.S., Shasha, D., Concert, C., Ishihara, D., Lin, W., Shourbaji, R.A., Ryniak, M., Gamez, M.E., Lukens, J.N., Li, Z., Culliney, B.E., Khorsandi, A.S., Tran, T., Jacobson, A., Manolidis, S., Schantz, S., Urken, M., Persky, M.S., Harrison, L.B., 2014. Initial experience with oropharynx-targeted radiation therapy for metastatic squamous cell carcinoma of unknown primary of the head and neck. *Anticancer Res.* 34 (January (1)), 243–248.
- Müller von der Grün, J., Tahtali, A., Ghanaati, S., Rödel, C., Balermias, P., 2017. Diagnostic and treatment modalities for patients with cervical lymph node metastases of unknown primary site – current status and challenges. *Radiat. Oncol.* 12 (May (1)), 82. <https://doi.org/10.1186/s13014-017-0817-9>.
- Nieder, C., Gregoire, V., Ang, K.K., 2001. Cervical lymph node metastases from occult squamous cell carcinoma: cut down a tree to get an apple? *Int. J. Radiat. Oncol. Biol. Phys.* 50 (July (3)), 727–733.
- Perkins, S.M., Spencer, C.R., Chernock, R.D., Haughey, B.H., Nussenbaum, B., Adkins, D.R., Kuperman, D.L., Thorstad, W.L., 2012. Radiotherapeutic management of cervical lymph node metastases from an unknown primary site. *Arch. Otolaryngol. Head Neck Surg.* 138 (July (7)), 656–661.
- Richards, T.M., Bhide, S.A., Miah, A.B., Del Rosario, L., Bodla, S., Thway, K., Gujral, D.M., Rooney, K.P., Schick, U., McGovern, T., Grove, L., Newbold, K.L., Harrington, K.J., Nutting, C.M., 2016. Total mucosal irradiation with intensity-modulated radiotherapy in patients with head and neck carcinoma of unknown primary: a pooled analysis of two prospective studies. *Clin. Oncol. (R. Coll. Radiol.)* 28 (September (9)), e77–84.
- Sanguineti, G., Pai, S., Agbahiwe, H., Ricchetti, F., Westra, W., Sormani, M.P., Clemente, S., Califano, J., 2014. HPV-related oropharyngeal carcinoma with Overt Level II and/or III metastases at presentation: the risk of subclinical disease in ipsilateral level IB, IV and V. *Acta Oncol.* 53 (May (5)), 662–668. <https://doi.org/10.3109/0284186X.2013.858825>.
- Sher, D.J., Balboni, T.A., Haddad, R.I., Norris, C.M., Jr, Posner, M.R., Wirth, L.J., Goguen, A., Annino, D., Tishler, R.B., 2011. Efficacy and toxicity of chemoradiotherapy using intensity-modulated radiotherapy for unknown primary of head and neck. *Int. J. Radiat. Oncol. Biol. Phys.* 80 (August (5)), 1405–1411.
- Sher, D.J., Adelstein, D.J., Bajaj, G.K., Brizel, D.M., Cohen, E.E.W., Halthore, A., Harrison, L.B., Lu, C., Moeller, B.J., Quon, H., Rocco, J.W., Sturgis, E.M., Tishler, R.B., Trotti, A., Waldron, J., Eisbruch, A., 2017. Radiation therapy for oropharyngeal squamous cell carcinoma: executive summary of an ASTRO Evidence-Based Clinical Practice Guideline. *Pract. Radiat. Oncol.* 7 (July-August (4)), 246–253. <https://doi.org/10.1016/j.prro.2017.02.002>.
- Shoushtari, A., Saylor, D., Kerr, K.L., Sheng, K., Thomas, C., Jameson, M., Reibel, J., Shonka, D., Levine, P., Read, P., 2011. Outcomes of patients with head-and-neck cancer of unknown primary origin treated with intensity-modulated radiotherapy. *Int. J. Radiat. Oncol. Biol. Phys.* 81 (November (3)), e83–91.
- Straetmans, J., Vent, J., Lacko, M., Speel, E.J., Huebbers, C., Semrau, R., Hoebbers, F., Mujagic, Z., Klusmann, J.P., Preuss, S.F., Kremer, B., 2015. Management of neck metastases of unknown primary origin united in two European centers. *Eur. Arch. Otorhinolaryngol.* 272 (January (1)), 195–205.
- Strojan, P., Ferlito, A., Medina, J.E., Woolgar, J.A., Rinaldo, A., Robbins, K.T., Fagan, J.J., Mendenhall, W.M., et al., 2013. Contemporary management of lymph node metastases from an unknown primary to the neck: I. A review of diagnostic approaches. *Head Neck* 35 (January (1)), 123–132. <https://doi.org/10.1002/hed.21898>.
- Villeneuve, H., Després, P., Fortin, B., Filiou, E., Donath, D., Soulières, D., Guertin, L., Ayad, T., Christopoulos, A., Nguyen-Tan, P.F., 2012. Cervical lymph node metastases from unknown primary cancer: a single-institution experience with intensity-modulated radiotherapy. *Int. J. Radiat. Oncol. Biol. Phys.* 82 (April (5)), 1866–1871.
- Waltonen, J.D., Ozer, E., Hall, N.C., Schuller, D.E., Agrawal, A., 2009. Metastatic carcinoma of the neck of unknown primary origin: evaluation and efficacy of the modern workup. *Arch. Otolaryngol. Head Neck Surg.* 135 (10), 1024–1029.

- Wong, W.L., Sonoda, L.I., Gharpurhy, A., Gollub, F., Wellsted, D., Goodchild, K., et al., 2012. 18F-fluorodeoxyglucose positron emission tomography/computed tomography in the assessment of occult primary head and neck cancers—an audit and review of published studies. *Clin. Oncol. (R. Coll. Radiol.)* 24, 190–195.
- Yu, Y., Daly, M.E., Farwell, D.G., Luu, Q., Gandour-Edwards, R., Donald, P.J., Chen, A.M., 2015. Level IB nodal involvement in oropharyngeal carcinoma: implications for submandibular gland-sparing intensity-modulated radiotherapy. *Laryngoscope* 125 (March (3)), 608–614. <https://doi.org/10.1002/lary.24907>.
- Zhang, F., Cheng, Y.K., Li, W.F., Guo, R., Chen, L., Sun, Y., Mao, Y.P., Zhou, G.Q., Liu, X., Liu, L.Z., Lin, A.H., Tang, L.L., Ma, J., 2015. Investigation of the feasibility of elective irradiation to neck level Ib using intensity-modulated radiotherapy for patients with nasopharyngeal carcinoma: a retrospective analysis. *BMC Cancer* 15 (October), 709. <https://doi.org/10.1186/s12885-015-1669-z>.